

REFLECT

d e n t a l p e o p l e f o r d e n t a l p e o p l e 0 2 / 1 0

Esthetic restoration

Tooth reconstruction with the composite IPS Empress® Direct

A particular challenge

Reconstruction of a central incisor with an implant-borne restoration

Keeping up with the times

Possibilities of high-quality temporization

Editorial

Dear Reader



You are holding the latest edition of Reflect in your hands. The international Ivoclar Vivadent customer magazine was first published in 2003 and is distributed worldwide in six languages.

It therefore fills me with pride to present you with our brainchild, which has grown over the years and whose quality will hopefully appeal to most of you.

This customer magazine is the result of a close cooperation between dentists and dental technicians.

At Ivoclar Vivadent France, and also at the other Ivoclar Vivadent organizations, we hold a firm belief that a close interplay between dentists and dental technicians is a necessary and indispensable prerequisite to successfully fabricate restorations and meet the patient demands, particularly in the light of the fact that, thanks to the new technologies, patients are becoming increasingly well informed about dental treatments.

In this issue, you will find numerous articles which are the fruit of such a collaboration and resulted from an intense exchange of ideas and know-how between dentist and technician.

The demand for esthetic dental restorations is continually increasing in France. The same could be said for the specialty in dentistry that aims at offering patients enhanced comfort by means of implant technology. Our customers are most interested in such technologies, and today's developments in this field can be interpreted as an answer to the requirements of tomorrow.

This issue covers a wide range of topics: techniques for the fabrication of veneers, direct restorations placed with our latest, highly appreciated esthetic composite IPS Empress® Direct or the latest state of technology in the field of all-ceramics for implant-borne restorations – all topics which I am sure you will find interesting.

I hope that you will enjoy this issue and that this magazine may become a constant source of reference in your daily work.

Best regards from France

A handwritten signature in blue ink, consisting of a large, stylized 'H' followed by a vertical stroke and a horizontal stroke extending to the right.

Henri Rochet
General Manager
Ivoclar Vivadent France

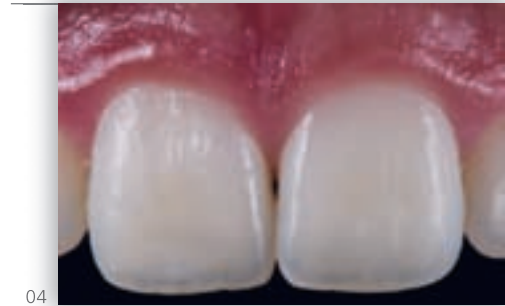Opalescence in natural enamel, reddish-orange effect in transmitted light (image: Dr Eduardo Mahn)

Editorial

- Close cooperation between dentists and dental technicians is the key to success* 02
Henri Rochet (F)

Dental medicine

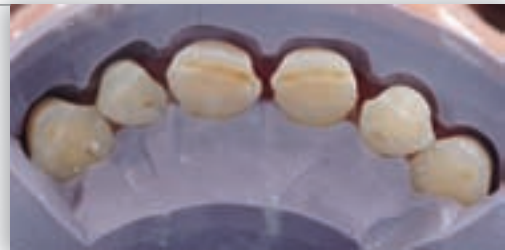- Esthetic restoration created with composite* 04
Dr Anna Salat Vendrell (E)
- Predictable results* 06
Wilson J Kwong, DMD (CDN)



04

Teamwork

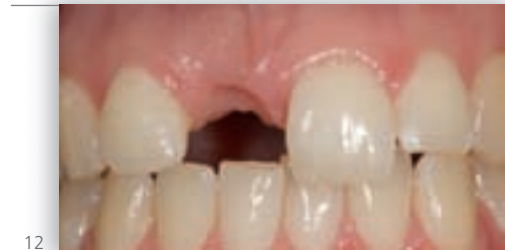- Radiant, beautiful anterior teeth* 09
Dr Stefen Koubi and Gérald Ubassy, DT (F)
- A particular challenge* 12
Dr Michael Fischer and Benjamin Votteler, MDT (D)
- Keeping up with the times* 16
PD Dr Stefan Holst, Nicola Pfennig, MDT, and Prof Dr Manfred Wichmann (D)



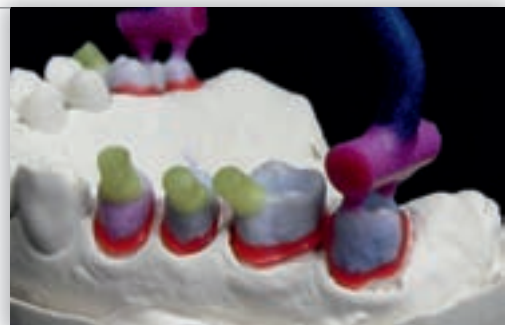09

Dental technology

- Combination of digital and analogue techniques* 19
Dr Gunpei Koike (JP)
- All-ceramics encounter PFM ceramics* 22
Hana Jelínková (CZ)



12



22

PUBLISHER'S CORNER

Publisher	Ivoclar Vivadent AG Bendererstr 2 9494 Schaan / Liechtenstein Tel +423 / 235 35 35 Fax +423 / 235 33 60	Coordination	Lorenzo Rigliaco Tel +423 / 235 36 98
Publication	3 times a year	Editorial office	Dr R May, N van Oers, L Rigliaco, T Schaffner
Total circulation	70,600 (Languages: German, English, French, Italian, Spanish, Russian)	Reader service	info@ivoclarvivadent.com
		Production	teamwork media GmbH, Fuchstal/Germany

Esthetic restoration created with composite

Clinical case: tooth reconstruction with IPS Empress® Direct

Dr Anna Salat Vendrell, Barcelona/Spain

The new generation of resin composite materials in combination with modern layering techniques allows today's practitioners to treat their patients with minimally invasive, highly esthetic direct restorations. Due to their enhanced properties, these materials produce results that are hardly distinguishable from the natural dentition, especially with regard to colour, which is particularly desirable in anterior teeth.

The new composite IPS Empress Direct enables us to create restorations that are almost invisible to the human eye. The appropriate increment technique together with correct handling of the materials and high-gloss polishing produces predictable, esthetic results directly in the mouth. Because of its nano-hybrid structure, the material can also be used to restore posterior teeth.

IPS Empress Direct materials are available in various levels of opacity, translucency and brightness. By combining the different materials, tooth-like light scattering can be achieved. The working steps of the technique used to place IPS Empress Direct are described in this article.

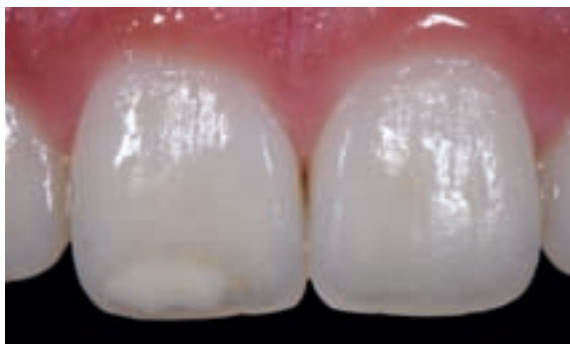

Fig 1 Preoperative situation

Clinical case: step-by-step restorative procedure

A young patient presented with a defective resin composite filling in tooth 11. The margin was no longer tight and the interface between the tooth structure and the restoration showed staining. What is more, the chroma, opalescence and shade of the filling did not correspond to that of the natural dentition (Fig 1).

According to the treatment plan the filling would be removed and the cavity prepared along minimally invasive principles and the tooth restored with a direct resin composite. In order to achieve impeccable integration of the restoration in the oral environment and an esthetic smile line with a uniform colour, the composite would have to be placed using the increment technique. As the cavity had walls on all sides, there was no need to create a wax-up or a silicone template to restore the tooth shape. A layering scheme was established before the treatment started.

During the dental examination, the general preoperative situation, the natural colour of the patient's teeth and individual characteristics were photographically documented. The layering scheme was prepared on the basis of the photographs. The different materials that would be used for the restoration were established in the process. In order to reproduce the special characteristics of the patient's tooth anatomy, the appropriate dentin and enamel shades were selected along with an opalescent material and a white-opaque material (from the IPS Empress Direct range).

At a second appointment, the operating field was isolated with a rubber dam, since absolute moisture control is indispensable in the placement of resin composites (Fig 2). The outer margins of the old filling were traced with a pencil. This was done to highlight the transition between the filling and the tooth structure in the removal of the old filling. A small chamfer was prepared on the vestibular side, as this is indicated for this type of restoration (Fig 3). Next,

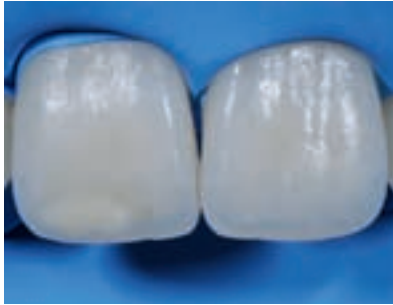

Fig 2 Absolute isolation of the operating field with a rubber dam is the ideal form of moisture control.

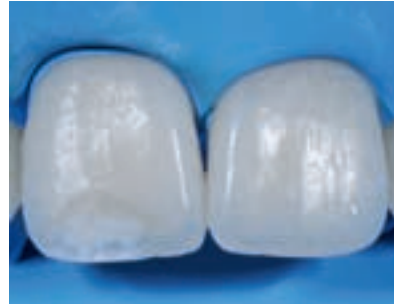

Fig 3 Preparation of a small circular chamfer

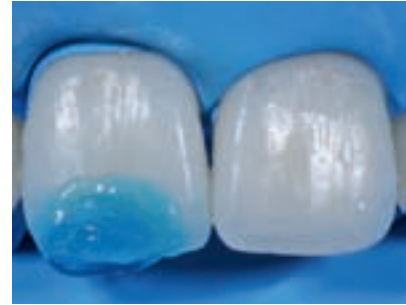

Fig 4 Etching with 37-percent phosphoric acid

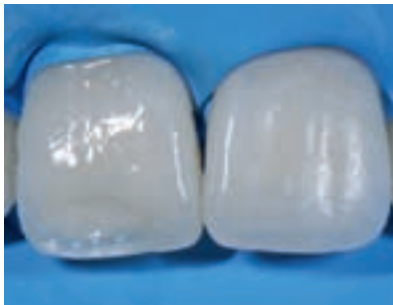

Fig 5 Application of the adhesive

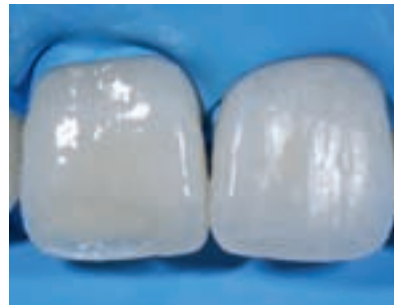

Fig 6 Application of the dentin material in the appropriate shade, that is, the appropriate translucency/opacity

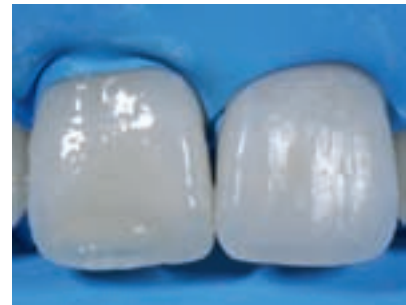

Fig 7 Application of the opalescent material in the enamel part of the tooth

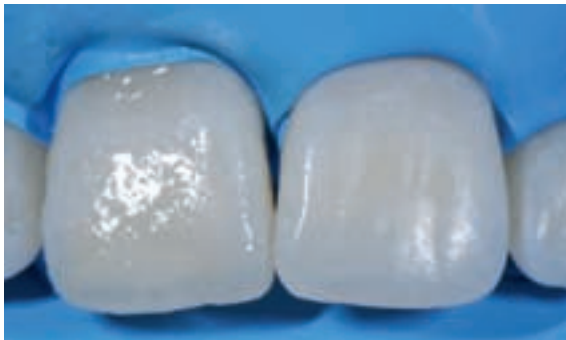

Fig 8 Application of the enamel material on the entire facial part of the restoration

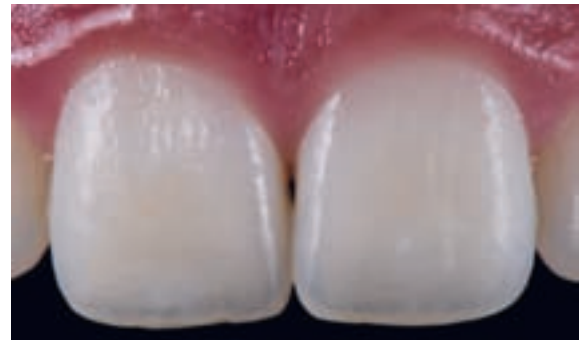

Fig 9 Restoration one week after it was placed

the enamel and dentin were etched with 37-percent phosphoric acid (Total Etch) and a three-component adhesive (Syntac®) was applied (Figs 4 and 5).

To obtain the desired tooth shade, the dentin part of the restoration was built up first with dentin material (IPS Empress Direct Dentin A2) (Fig 6). A translucent and opalescent material (Trans Opal from the IPS Empress Direct range) was used to build up the enamel part (Fig 7). Thin white-opaque strips (IPS Empress Direct Bleach XL) were applied over the dentin segment to enhance the brightness. Finally, an appropriately shaded enamel material (IPS Empress Direct Enamel A2) was placed over the entire facial surface of the restoration to cover all the previously placed materials (Fig 8). The creation of surface texture as well as finishing and polishing are important working steps in imparting a restoration with a true-to-nature appearance. As a result, they have to be given the due attention. In the present case, the surface texture was created with diamond burs at low speed. This allowed the procedure

to be precisely controlled. A three-step silicone polishing system (Astropol®) was used to finish and polish the restoration. Finally, the restoration was polished to a high gloss finish using aluminium oxide and diamond pastes (Shiny System, Micerium) and brushes and felt wheels.

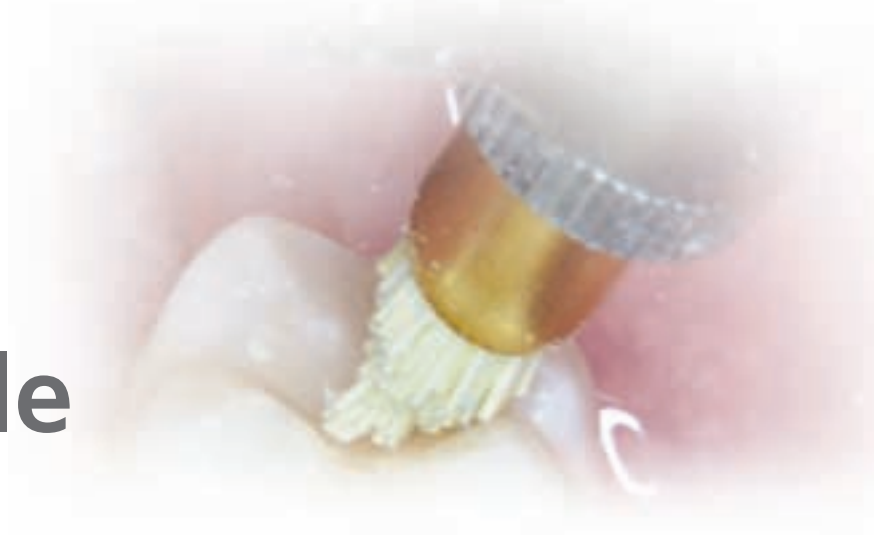It is worthwhile to recall the patient for a third appointment to make sure that the restoration blends into the natural environment when the tooth is moist and to establish whether or not any shape or colour adjustments need to be made (Fig 9). □

Contact details:

Dr Anna Salat Vendrell
C/ Frederic Corominas nº 48
Torrelles de Llobregat
08629 Barcelona
Spain
annasalat@hotmail.com



Predictable results



The restoration of teeth with Tetric EvoCeram®

Wilson J Kwong, DMD, Vancouver/Canada

Tetric EvoCeram is an innovative, nano-optimized, universal hybrid composite that offers many advantageous features. Tetric EvoCeram is composed of three different types of nano-particles, which include fillers, pigments and a modifier. These combine to create a singular material that presents improved handling properties, a non-sticky consistency, enhanced stability and excellent shade adaptation.

Tetric EvoCeram also demonstrates other characteristics that are favourable to clinicians, allowing them to work more effectively and efficiently. For example, Tetric EvoCeram exhibits low shrinkage, low wear rates and is easy to polish, unlike many other restorative materials. Additionally, the formulation of this nano-optimized composite creates the ability to blend it completely with the tooth's natural structure or with the surrounding natural dentition. Due to these characteristics, restorations created with Tetric EvoCeram are long-lasting and demonstrate a natural fluorescence, along with a high radiopacity.

Case presentation

In this case, the patient was a 58-year-old male who wanted to upgrade his old amalgam restorations to bonded composites (Fig 1). The patient also presented with an active underlying immunosuppressive condition, which was discussed during pre-treatment planning. During this planning, the patient asked for "white fillings" to replace the previous amalgams on the lower left first and second molars (teeth 46 and 47).

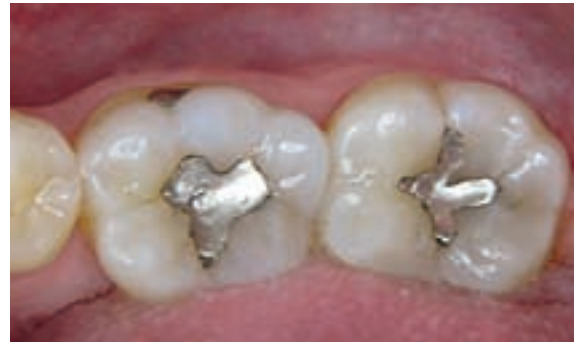

Fig 1 A preoperative view of the patient's old amalgam restorations before being replaced with Tetric EvoCeram

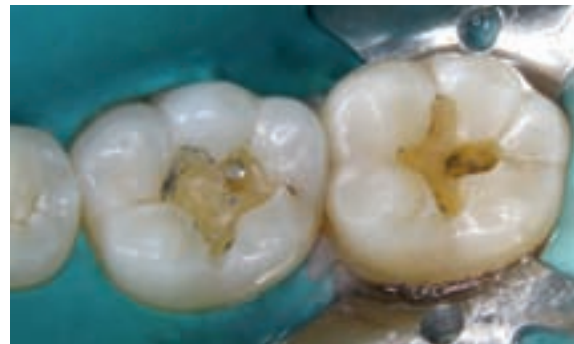

Fig 2 The amalgams were removed and the caries underneath excavated.

Consequently, the old amalgams were removed, and the caries underneath were identified and then excavated (Fig 2). Evidence of leakage was present in the preparation, and some of the grooves were stained. However, the integrity and structure of the teeth were good.

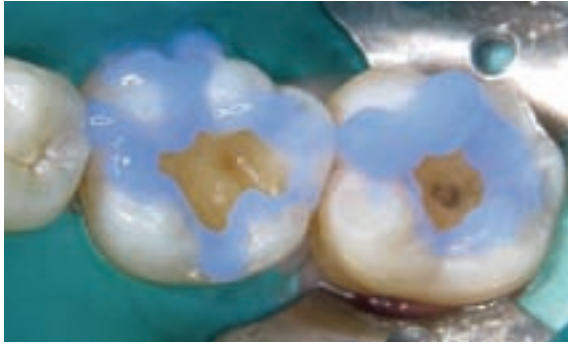


Fig 3 The enamel was etched for 15 seconds.

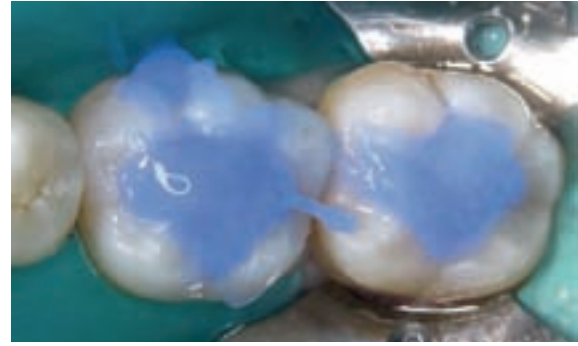


Fig 4 The dentin was etched for 10 seconds.

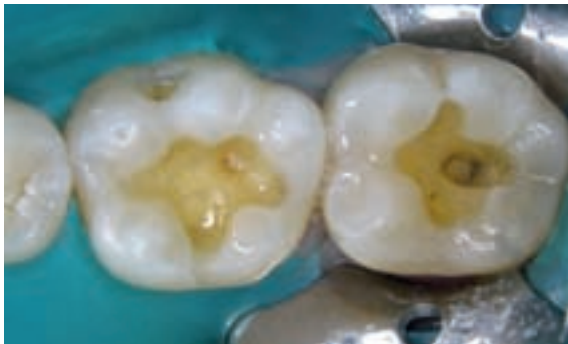

Fig 5 The Excite F bonding agent with fluoride was placed using a VivaPen.

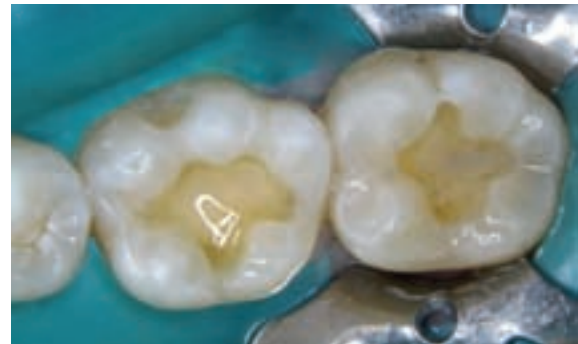

Fig 6 Shade A1 of Tetric EvoFlow was placed on the floor of the preparation.

The cavity preparation was then rinsed with a cleaning solution of hydrogen peroxide (3%) and chlorhexidine (2%) in order to remove any debris that was present. Following cleaning, the enamel was etched for 15 seconds using an etchant gel (Fig 3). The dentin was then etched for 10 seconds, giving the enamel a full 25 seconds of etching (Fig 4). Once the preparation was etched to satisfaction, a copious amount of water lavage was used to remove all the etching gel and excess material.

Excite® F, a fluoride-containing bonding agent in the VivaPen delivery form was liberally placed in the preparations in an agitating motion for 20 seconds. This was followed by light air drying to evaporate the solvent, and then the preparations were light-cured for 10 seconds. This process was also completed at angles around the cavity preparations to cure undercut areas (Fig 5).

A flowable, light-curing nano-hybrid composite (Tetric EvoFlow®), in shade A1, was then placed on the floor of the preparation and light cured for 20 seconds (Fig 6). The depth of the cavity preparation was only 3 mm, so that two increments were sufficient to build up the entire restoration. A universal, light-curing radiopaque nano-hybrid composite (Tetric EvoCeram) was then placed in one increment and sculpted with a cylindrical instrument (TINBRDILLY, Brasseler) and a flat composite instrument (Mini 3, Hu-Friedy). The preparation was cured for 20 seconds, and Tetric® Color was placed into the grooves to accentuate the anatomy. This was followed by a final light-cure and flash removal with fluted carbide finishing burs (Axis Dental) (Fig 7).

Once the final occlusal adjustments had been made, final polishing was performed using rubber points and wheels (Astropol®) as well as brushes (Astrobrush®) (Fig 8). Astrobrush was also used for and in the grooves.

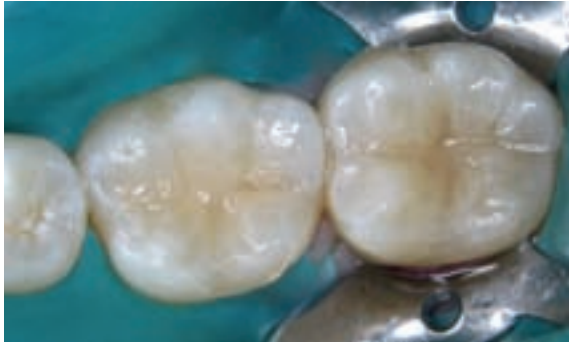

Fig 7 Tetric Color was applied into the grooves to accentuate the anatomy.

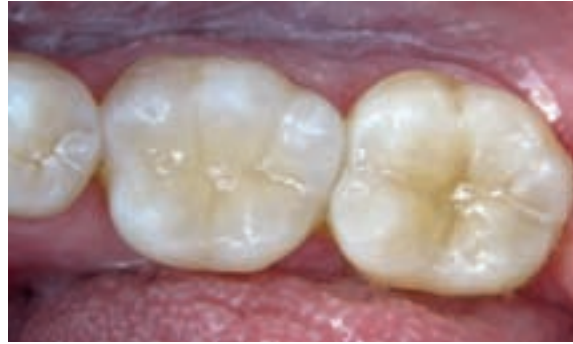
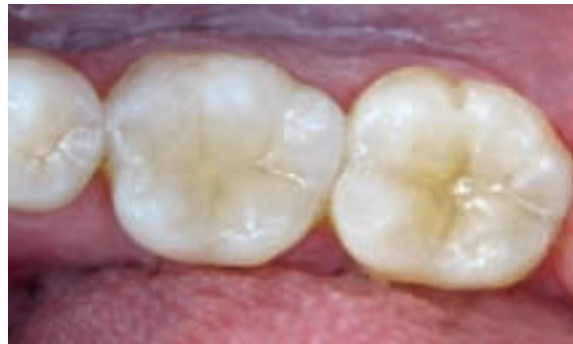
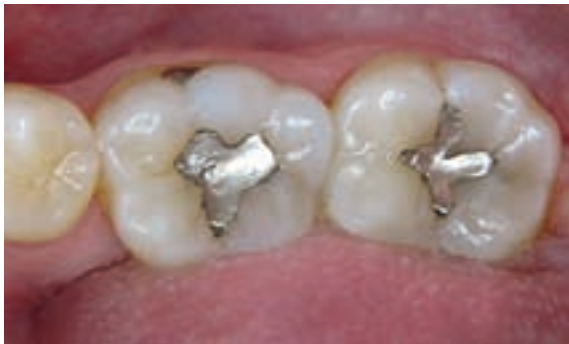Fig 8 Rubber points and wheels (Astropol) and brushes (Astrobrush) were used for occlusal adjustments and polish.



Figs 9 and 10 Before and after postoperative views of teeth 46 and 47

Conclusion

Tetric EvoCeram is a nano-optimized, universal hybrid composite suitable for anterior and posterior restorations. It is also ideal for replacing failing amalgam restorations (Figs 9 and 10). In particular, the material handles very well, with little tackiness on the instruments, and it polishes wonderfully. These characteristics also ensure that patients will be happy with the esthetics and function of their restorations. □

Contact details:

Dr Wilson Kwong Inc
Wilson J Kwong, DMD
650 41st Ave W, Vancouver, BC V5Z 2M9
Canada
wjkwong@me.com
www.smilesarebeautiful.com



Radiant, beautiful anterior teeth

Restoring a smile after severe periodontitis

Dr Stéphen Koubi, Marseille, and Gérald Ubassy, DT, Rochefort du Gard/both France

The loss of the interdental papillae is a grave consequence of periodontal disease. Surgical reconstruction is still not feasible. There are several approaches to reducing or masking the black triangles which occur as a consequence of the missing papillae. Conventional restorations are an option if the teeth additionally show increased mobility. If this is not the case, that is, if the periodontal tissue is healthy, it is crucial to find a biomimetic solution, meaning that the restoration should take esthetic, biomechanical and biological factors into account.

Initial situation

The treatment of missing papillae by means of ceramic veneers will be presented on the basis of a clinical case. A female patient aged around forty was unhappy with the look of her smile, which she described as “disgraceful”. The esthetic diagnosis consisted of an analysis of the features of the face, the smile, the teeth and the gingiva. The analysis (Fig 1) revealed the following findings:

- Face: tense and shy look due to self-consciousness about her teeth.
- Smile: considerable esthetic compromises due to the black triangles.
- Teeth: healthy triangular, curved teeth; the margins of the roots are visible.
- Gingiva: healthy periodontal tissue; interdental papillae are missing; the teeth are stable; recess at tooth 12.
- Radiological examination: regular alveolysis in the cervical third.

Procedure

The following procedure was determined on the basis of the analysis:

- surgical intervention at tooth 12 in order to increase the gingiva (transplantation of connective tissue)

- fabrication of a mock-up in order to visualize the final result
- tooth preparation on the basis of the mock-up
- temporization
- try-in of the veneers (adaptation, shape and shade)
- incorporation of final restoration.

Treatment course

Surgical intervention to increase the gingiva: Connective tissue was removed from a lobe which was moved towards the tooth crown. Before further treatment was conducted, a four-month healing phase was necessary.

Preparing the mock-up: A silicone matrix was fabricated on the basis of the wax-up, which was based on the findings of the esthetic analysis. The temporary restorations were fabricated with the help of the matrix from a self-curing, flowable Bis-GMA-based composite. This allowed us to discuss the restoration beforehand with the patient, who provided her input and approved of the restoration (Fig 2).

Preparation: In order to keep the depth in check and observe the biological concept, the drill was placed

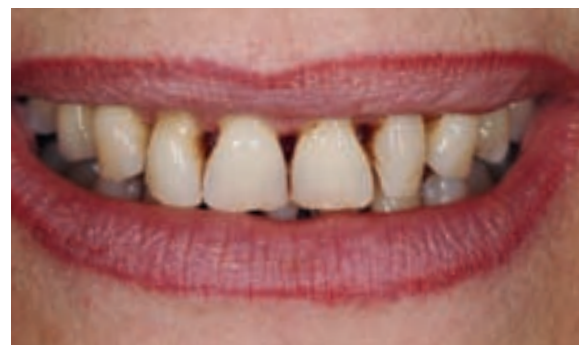

Fig 1 Preoperative view

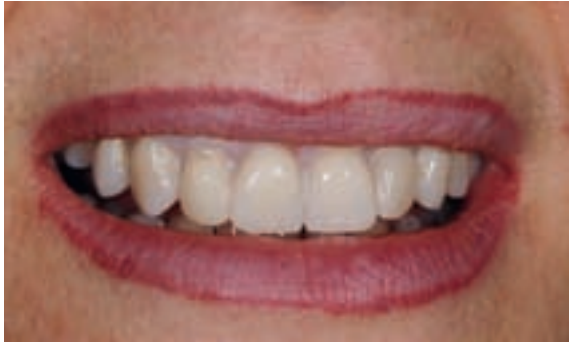

Fig 2 Mock-up

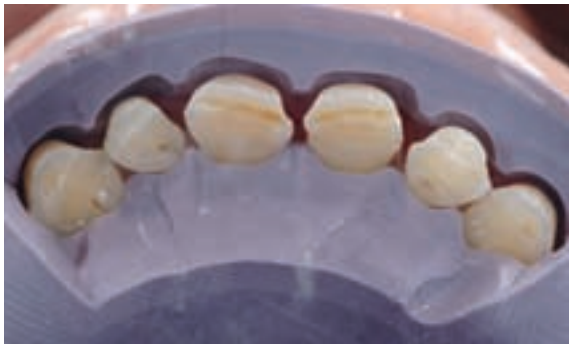

Fig 4 Checking the relation between the preparations and the volume of the final restoration with the help of a silicone matrix

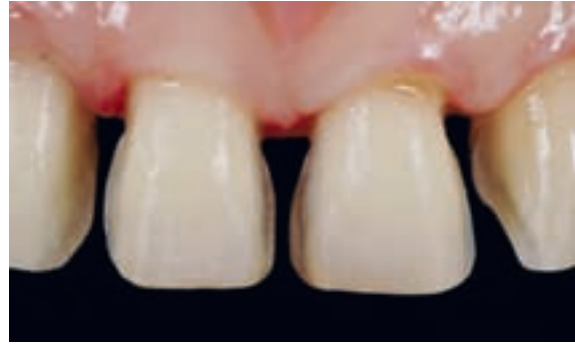

Fig 3 Preparations with subgingival margins in the proximal region

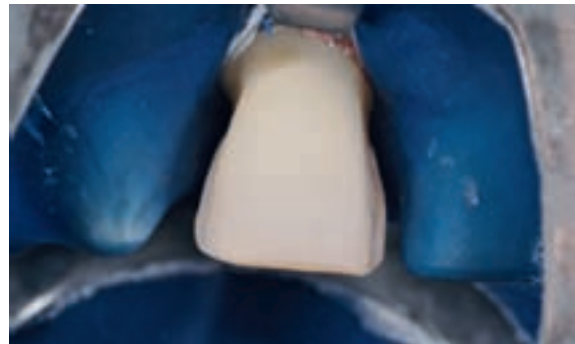


Fig 5 Isolating individual teeth in order to achieve optimum bonding

directly on the mock-up. With this procedure, a uniform thickness of approx 0.5 mm is achieved on the basis of the volume of the final restoration (cf Gürel 2006). After removing the preparation key (mock-up), the presence of larger, non-prepared enamel areas is observed. In the present case, the treatment protocol was slightly varied in view of the cervical preparation margins: Usually, the preparation margins are located above the gum line for veneer preparations; in this case, however, the margins had to be designed subgingivally (Fig 3). This approach was chosen for various reasons: In order to eliminate the black triangles, meet the biological requirements (cleaning and soft edges) and take the biomechanical properties of the ceramic (preventing non-supported areas in the ceramic) into account, only one single contact surface with a soft transition from the edge of the root to the margins of the contact surface could be designed to mask the missing papillae (Fig 4).

The all-ceramic veneers were fabricated with the IPS e.max® Press (MO1) lithium disilicate glass-ceramic material, and the incisal third was veneered with IPS e.max® Ceram. The pressed veneers, which showed a minimum thickness of 0.3 mm, feature a high stability and outstanding accuracy of fit on the one hand and excellent light-optical properties on the other.

Try-in of the IPS e.max Press veneers: After removing the temporary restorations, all veneers were tried in simulta-

neously. This enabled the overall appearance to be visualized. Subsequently, the accuracy of fit was checked. Variolink® Veneer Try-In paste was used for this procedure to simulate the effect of the cementation material on the shade of the restoration.

Clinical procedure: The veneers were individually cemented in the adhesive technique, starting with the incisors (Fig 5), followed by the lateral incisors and canines and so on, thus allowing the clinician to carry out corrections on the proximal areas of the less prominent teeth (distal surfaces of canines or premolars). The restorations were conventionally placed with Variolink Veneer. In a last step, the composite joints were carefully finished with a scalpel in order to maintain the surface gloss of the ceramic and the excellent fit in the periodontal tissue (Figs 6 to 8).

Note

Clear communication between the dentist and the dental technician is mandatory in clinical cases such as this to allow as much information as possible to be exchanged (models, images of the initial situation, images of the preparations and their shade, impression of the temporary restorations in place, shade determination). In the present case, it was agreed with the ceramist to design the margins of the contact surfaces on the stone model two millimetres from the papilla, because, for the papilla to grow back, the distance between the contact point and the tip

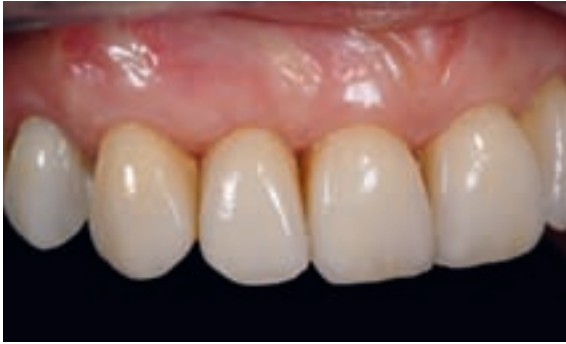

Fig 6 Lateral view of the IPS e.max Press veneers (from right)

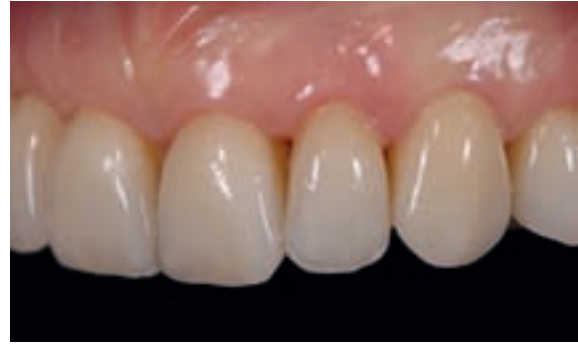

Fig 7 Lateral view of the IPS e.max Press veneers (from left)

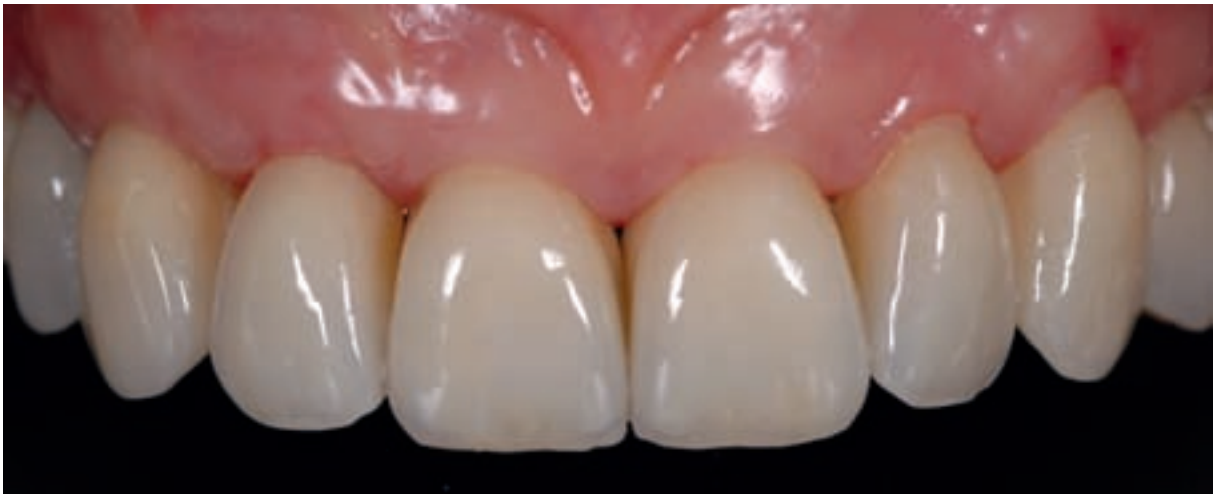

Fig 8 Frontal view of the restorations. An expansion of the interdental papillae can be observed.

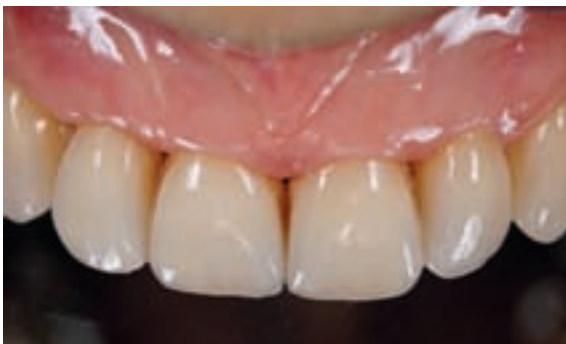

Fig 9 View of the maxillar teeth. The optical properties of IPS e.max Press material are particularly highlighted in this image.

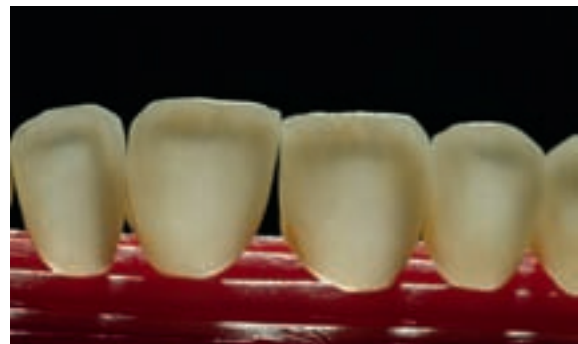

Fig 10 Light transmission through IPS e.max Press veneers

of the papilla must be less than five millimetres (Tarnow). After some months, the papilla will have grown and filled the small spaces that were reserved for it. This is also a confirmation of the biocompatibility of the lithium disilicate glass-ceramic IPS e.max Press (Figs 9 and 10).

By strictly observing the treatment strategy and using materials which show optimum optical and biomechanical properties, the patient's smile was modified and restored while abiding by the principles of minimally invasive dentistry.

I would like to thank Gérald Ubassy for his cooperation and his exceptional talent. □

Contact details:

Dr Stefen Koubi
51, rue de la Palud
13001 Marseille
France
koubi-dent@wanadoo.fr

Gérald Ubassy
Centre de Formation International
Route de Tavel
Impasse des Ormeaux
30650 Rochefort du Gard
France
contact@ubassy.com



A particular challenge

Reconstruction of a central incisor with an implant-borne restoration

Dr Michael Fischer and Benjamin Votteler, MDT, both from Pfullingen/Germany

A 28-year-old female fractured her right central incisor in a fall. Despite immediate dental treatment, the natural tooth could not be saved and had to be extracted by her dentist. A removable temporary denture was fabricated and inserted to replace the missing tooth 11. The patient was referred to us for the placement of the implant and the subsequent prosthodontic work. Due to the good condition of the hard and soft tissue, pre-implantological augmentation was unnecessary. As Figure 1 clearly shows, the frenulum labii extended into the implant zone. As a result, it was relocated during the implant procedure. This measure was taken to prevent gingival recession around the implant bed at a later stage. After three months of non-submerged healing, an impression was taken with a tray that was modified to allow the impression post to project. A master cast was subsequently fabricated in the dental laboratory.

The successful outcome of such a difficult case (high smile line, normal to pronounced curving of the gingiva, thin soft tissue) depends on two main factors: first, the proper three-dimensional positioning of the implant and second, the material and design of the abutment.

We prefer to use zirconium oxide abutments with a titanium base. This type of abutment ensures excellent fit in the implant due to the industrially milled titanium base. Furthermore, the zirconium oxide abutment (emergence profile) can be individually customized.

The emergence profile of tooth 11 was established according to the following procedure. On a second model, the contralateral incisor, tooth 21, was ground away at gingival level and the root diameter was marked. A thin piece of paper was placed over the area and the profile was traced. The profile was cut out, mirrored and then transferred to the master model. This allowed the emergence profile to be cut to the

implant shoulder. Progressive opening towards the coronal aspect was of importance. Of course, the emergence profile of the abutment could also have been moulded in several stages using provisional restorations. However, we have had much success with the described method (Fig 2).

Next, tooth 11 was waxed up. The wax-up was then used to create a silicone template of the palatal aspect and another one of the vestibular aspect. The abutment base ("ST", Astra Tech, Sweden) was screwed into the laboratory analogue and the ground emergence profile as well as the base were isolated (ceramill sep) and light-curing resin composite (ceramill gel, both from Girschbach, Austria) (Fig 3) was applied. Preliminary curing was necessary at this stage to achieve complete polymerization of the light-curing material in the depth of the sulcus. Subsequently, the superingival part of the abutment was built up and light-cured.

In order to obtain flat surfaces and a defined preparation margin along the abutment, the cervical areas were milled para-gingivally. The labial-proximal and the palatal surfaces were machined to produce a conical shape with a 2-degree gradient.

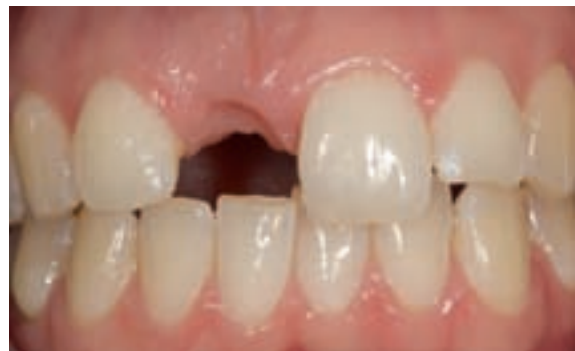

Fig 1 The frenulum labii has to be relocated to prevent recession around the implant bed at a later stage.

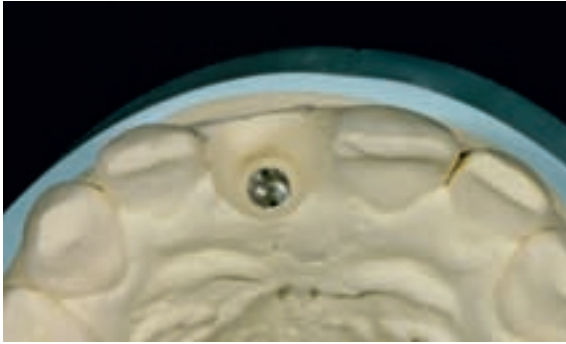


Fig 2 Forming of the emergence profile on the basis of the adjacent tooth

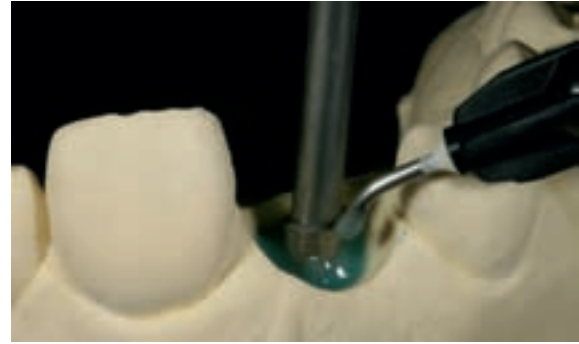


Fig 3 Modelling of the customized abutment with light-curing resin

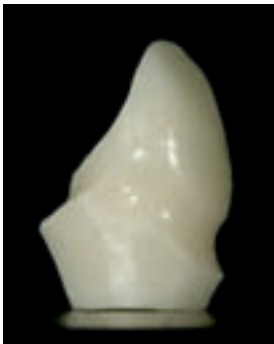

Fig 4 The shaded and sintered zirconium oxide abutment

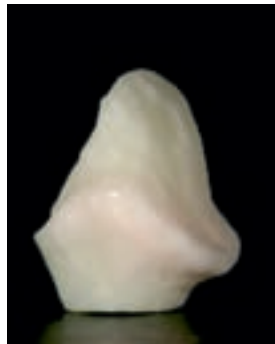

Fig 5 The fired-on ceramic shoulder (IPS e.max Ceram)

The gradient and the palatal surface were cut by hand. The available space was checked with the previously fabricated templates.

In my laboratory the abutments are rendered in zirconium oxide using the copy milling technique. Alternatively, this step can be conducted with CAD/CAM systems by using the double scan method or an abutment design software.

The green body was smoothed after copy milling. A chamfer was cut at the gingival level for the subsequent creation of a ceramic shoulder. Then the restoration was shaded and sintered (Fig 4). After the sintering process, only very fine adjustments had to be made in order to ensure the final fit. In this case, the abutment was coated with IPS e.max® Ceram ZirLiner. Next, the reduced shoulder made of IPS e.max Ceram was briefly fired on the restoration (Fig 5). Furthermore a thin layer of ceramic was placed over the entire zirconium oxide abutment. The abutment created in this way has three advantages:

1. The glass-ceramic coating allows the abutment to be etched, which is a prerequisite for adhesive bonding of the crown and the abutment.
2. Light transmission in the gingiva increases dramatically due to the fact that light transmission of zirconium oxide layers of 3 mm in the paragingival areas of the abutment drops to almost zero.
3. Fluorescence: The fluorescence of zirconium oxide is quite low. However, once IPS e.max Ceram ZirLiner and the layering ceramic have been applied to the restoration, it increases significantly.

An important aspect of this type of abutment is the bond between the titanium base and the zirconium oxide. We advise against using popular laboratory luting agents such as Nimetic™ Cem or AGC® Cem for this purpose. A study, which has shed some light on this frequently neglected working step, has been conducted by Prowital under the direction of R Meyer, MDT.

The latest development in this dental industry segment is Multilink® Implant (Ivoclar Vivadent). This material has taken the standard regarding the handling and physico-chemical properties of these products to a higher level. According to the above study, the bond strength of this self-curing luting composite, which can be light cured if desired, is 45 percent higher than that of the previous benchmark Panavia™ F 2.0 (Kuraray, Japan) and about 25 percent higher than that of RelyX™ Unicem (3M ESPE, USA). The fact that Multilink Implant quickly cures without exposure to light is an advantage when thick abutments are involved, since in these cases light may not be able to penetrate into all areas of the restoration and may therefore fail to adequately cure the cement.

The highest bonding values in this study, in which surface conditioning and curing methods were examined, were achieved under the following conditions. The inner surface of the zirconium oxide abutment was cleaned with 110 µm Al₂O₃ at 1 bar pressure and the titanium base was cleaned with 50 µm Al₂O₃ at 2 bar pressure. Both bonding surfaces were coated with Monobond® Plus, which was allowed to react for one minute before it was dried with blown air. Next, Multilink Implant was applied on the inner surface of the ZrO₂ abutment and the titanium base was attached to it (Fig 6). Like all composites, Multilink Implant is susceptible to oxygen inhibition, that is, the uppermost layer (approx 100 µm) of the material does not completely cure during the polymerization process because it is exposed to oxygen. There are several ways to prevent this problem:

1. After the zirconium part has been attached to the bonding surface, excess composite is completely removed and a glycerine gel (eg Airblock™, Dentsply, USA) is applied to prevent the formation of an inhibited layer.



Fig 6 Optimum cementation with Multilink Implant



Fig 7 An impeccable joint

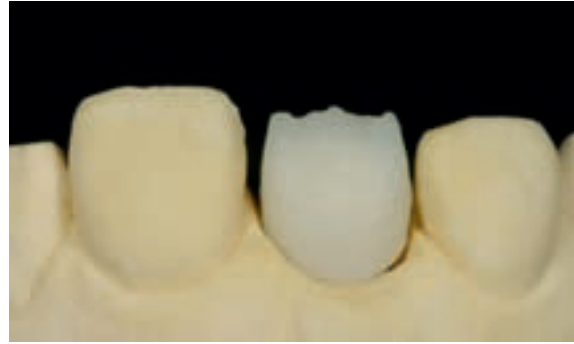

Fig 8 The IPS e.max Press lithium disilicate coping after foundation firing

2. The excess cement is left in place. The cement joint is not cleaned after the two parts have been joined. Rather, the excess cement is chipped away with a sharp instrument after polymerization. Care must be taken not to damage the cement joint at this stage.

Finally, the cement joint was finished and polished to a high gloss with rubber polishers. Our efforts were rewarded with an impeccable joint (Fig 7).

In the next step, the coping for the IPS e.max[®] lithium disilicate (LS₂) glass-ceramic crown was fabricated. The screw access hole was sealed (eg with silicone putty) and the abutment was treated like a natural abutment tooth, in other words, it was coated with spacer (eg Ibuki die spacer, Anaxdent, Germany).

The coping was waxed up to create a reduced tooth shape (anatomical). This was done to ensure controlled shrinkage during the veneering step. Depending on the tooth that is being restored, that is, depending on its translucency and brightness, either an IPS e.max[®] Press LT or an MO ceramic ingot is used (LT = low translucency, MO = medium opacity) to press the coping.

After the restoration had been pressed, the sprues were removed and the coping was carefully tried in and finished. Foundation firing was conducted before the main firing cycle because of the following reasons (Fig 8):

1. It enhances the bond between the layering material and the pressed coping.
2. The coping is characterized with fluorescent stains in order to create areas where the chroma is higher right at the beginning of the procedure. After the characterization step, dentin powders, for example, are sprinkled on the coping, which is subsequently fired. For foundation firing, I use a temperature that is 20 °C higher than the temperature of the first dentin firing cycle. The fired layer contains all the internal characteristics of the tooth.

For the second firing, the tooth was built up slightly larger than its ultimate size. As a result, the shape and surface texture of the restoration could be adjusted to the characteristics of the adjacent tooth by grinding (Fig 9).

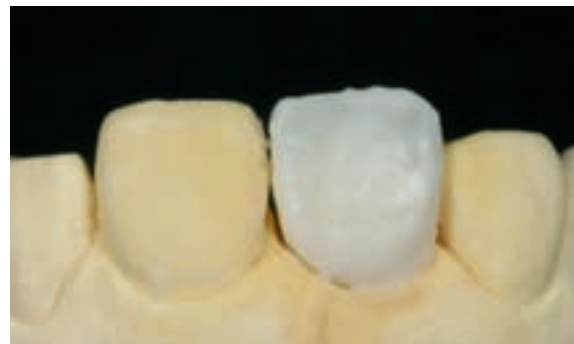

Fig 9 Application of incisal materials for the second firing

During glaze firing, I maintained the final temperature for only 20 seconds, in order to obtain a silky matt surface. The desired level of gloss was subsequently achieved with a polishing machine using a wet felt wheel and pumice. The inner surface of the crown was not sandblasted, as this would have compromised its strength.

After the restoration was tried in, the inner surface of the crown and the surface of the abutment were cleaned with alcohol.

In preparation for insertion, the ceramic surfaces were etched (eg with IPS[®] Ceramic Etching Gel). The surface of the abutment, which was covered with IPS e.max Ceram (nano-fluorapatite glass-ceramic), showed a large retentive etch pattern after a reaction time of 20 seconds (4.5% HF). The lithium disilicate inner side of the all-ceramic crown was also etched for 20 seconds. Finally, both parts were conditioned with silane (Monobond Plus). In order to prevent the luting composite from entering the sulcus, a retraction cord was placed (001 Ultrapac[®], Ultradent, USA).

The restoration was seated with a luting composite (eg Variolink[®] II, Variolink[®] Veneer or Multilink Implant). It is important to note that Variolink Veneer should only be used to place translucent crowns and restorations with light shades through which light can penetrate adequately, as this cement requires light to polymerize.

Nevertheless, a luting composite that cures only when it is exposed to light (eg Variolink Veneer) offers the operator the advantage of being able to remove all excess cement without any time constraints. Subsequently, the material was cured from all sides for



Fig 10 A radiant smile

30 seconds (the time depends on the curing light used). The retraction cord was removed and the restoration was carefully examined with surgical loupes for any remnants of excess cement. Three months after the crown was placed, the affected hard and soft tissues were in healthy condition (Figs 10 and 11).

Discussion

Tackling a complex abutment design of this kind is only possible if the gingival biotype is thin and normal (according to HP Weber/John Kois). Thin, scalloped gingival tissue (the keratinized gingiva is 0.6 to 0.9 mm thick) is characterized as follows:

- ❑ Small amount of attached gingiva
- ❑ Triangular clinical crown with narrow interdental contact zones
- ❑ Soft tissue recession as a reaction to surgical/prosthetic interventions
- ❑ Predisposition to the formation of defects due to resorption processes after tooth extraction with collapse of the interdental papillae
- ❑ Outline of a periodontal probe shows through the gingival tissue.

All these aspects have to be taken into consideration in order to achieve lifelike results. If the gingival biotype is thick (the keratinized gingiva is 1.0 to 1.3 mm thick), the selection of the abutment does not have such a great influence on the pink esthetics of the restoration. In these cases, a metal abutment or a zirconium oxide abutment without an additionally fired ceramic shoulder would suffice.

Nevertheless, zirconium oxide is far superior as an abutment material with regard to white esthetics. Unlike metal substrate materials, it allows light to penetrate from different angles (eg light from the side). The thick gingival biotype exhibits an even soft tissue and bone architecture:

- ❑ Minimal difference between buccal, marginal and proximal soft tissue and bone heights
- ❑ Short interdental papillae
- ❑ Fibrous character of soft tissue
- ❑ Tendency to scar
- ❑ Square anatomic crowns with rounded convex surface

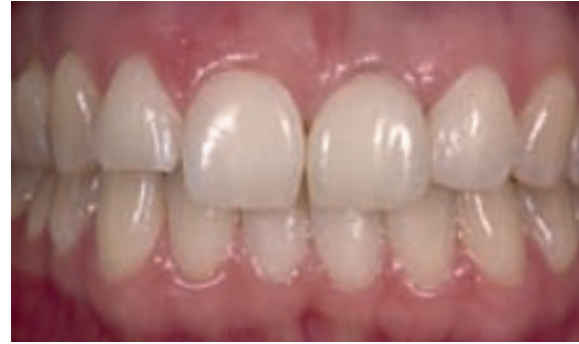

Fig 11 Close-up of the restoration three months after placement

- ❑ Large contact area between clinical crowns
- ❑ Minimal tendency to recede
- ❑ A periodontal probe does not show through the gingival tissue.

Non-submerged healing

The decision to follow a non-submerged protocol was based on the following reasons:

1. Ample time for maturation of the soft tissue before the prosthodontic work begins
2. Avoidance of a second surgical procedure
3. Maintenance of blood supply to the area
4. Reduction in the treatment time and less inconvenience for the patient (according to Anthony G Sclar).

This approach is only possible if adequate gingival attachment exists. If soft tissue has to be augmented, submerged healing is essential. In the present gingival biotype, the frenulum labii had to be relocated, since it extended into the attached gingiva and could have caused the tissue to recede.

In the case discussed, an inter-sulcular incision was made without a relieving incision. This approach allowed the vestibular bone lamella to be visually checked. Only very little connective tissue had to be removed. As a result, there was minimal bone loss. Scarring did not occur. ❑

Contact details:

Dr Michael Fischer
Hohestr. 9/1
72793 Pfullingen
Germany
dr.michel.fischer@web.de
www.drnichaelfisher.de

Benjamin Votteler, MDT
Dentaltechnik Votteler
GmbH & Co. KG
Arbach ob der Str. 10
72793 Pfullingen
Germany
benni@votteler.eu
www.votteler.eu





Keeping up with the times

Possibilities of high-quality temporization with Telio® CAD by NobelProcera™

PD Dr Stefan Holst, Erlangen, Nicola Pfennig, MDT, Munich,
and Prof Dr Manfred Wichmann, Erlangen/all from Germany

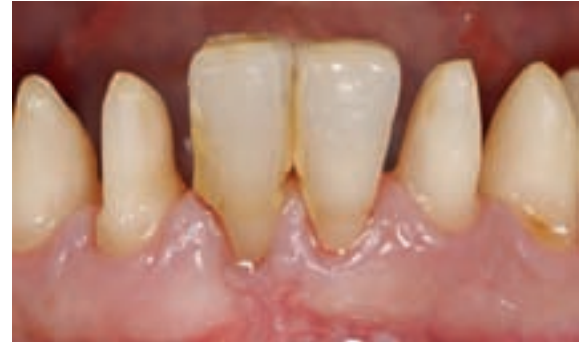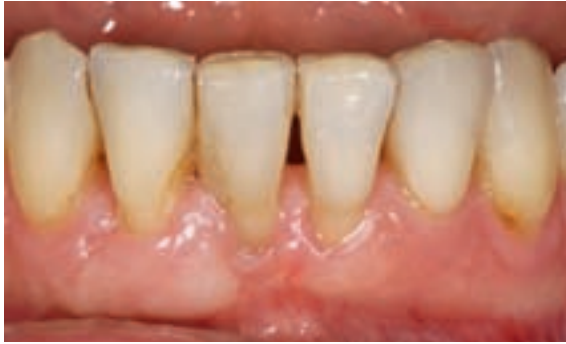Digitization has been advancing at a rapid pace in dentistry in recent years and will result in significant structural changes in day-to-day work processes. Today, the combination of advanced materials and CAD/CAM manufacturing techniques (Computer-Aided Design/Computer-Aided Manufacturing) allows the industrial production of prosthetic components for virtually every indication. While at present these new technologies are mainly used in the dental laboratory, the second wave of technological innovation will also result in changes in the work routines of dental practices. Costly and time-consuming steps such as the design of models and the manual fabrication of models and superstructures can be outsourced and enable dental professionals to focus on central aspects, such as treatment planning, advice-giving and customized completion of restorations. The answer to the question if these changes should be regarded as positive is 'yes'. The main reasons for welcoming these technologies is the fact that they ensure a consistently high product quality based on industrial manufacturing processes, excellent biocompatibility of the materials used for these applications and – in comparison to cast metal techniques – considerably less expenditure of time while the accuracy of fit and precision are increased. All these factors result in high-quality tooth replacements for all patient cases, independent of whether an inexpensive standard treatment option or a highly esthetic solution is selected.

CAD/CAM technology – A choice of materials to suit every clinical indication

A multitude of materials can be used in conjunction with CAD/CAM technologies. These materials include ceramics, titanium, composites and base metal alloys (CoCr). Contrary to widespread belief, CAD/CAM technologies are suitable for more than only conventional crown and bridge restorations; modern systems cover a broad variety of indications, ranging from single crowns on natural abutments and individualized ceramic abutments on implants to wide-span superstructures on teeth or implants, which are either cemented or screwed in place.

Telio CAD by NobelProcera – Customized CAD/CAM temporaries for a diverse range of indications

While a large number of factors have to be taken into account when selecting the materials for a final prosthetic reconstruction, the necessity of providing optimal temporization should not be ignored. Temporaries are required in many cases: It may be necessary to monitor the oral situation over several months to evaluate a change in vertical jaw relations or to establish the long-term functionality of periodontally damaged teeth; the gums may need to heal first before the final restoration can be placed, particularly in conjunction with implant-borne reconstructions. In the past, this important treatment step was often associated with additional financial expense for the patient and in many cases was rejected for cost considerations. The high costs were mainly caused by the laborious methods required to produce customized composite temporaries in the dental laboratory. CAD/CAM technologies enable the rapid manufacture of highly accurate temporary restorations. If appro-



Figs 1a and b Intraoral view of the initial clinical situation before (a) and after (b) preparation of the abutment teeth. Teeth 31 and 41, which had to be extracted, were left in place when the impression for the long-term temporary was taken.

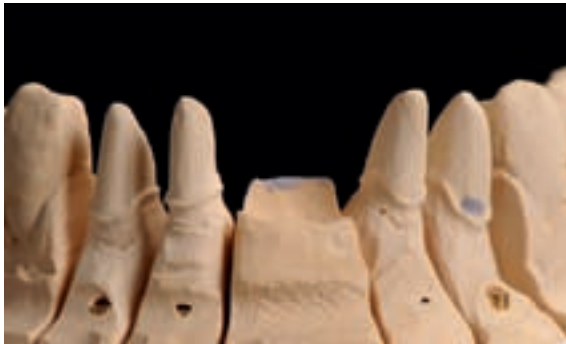

Fig 2 Master model with separated teeth 31 and 41, ready for scanning

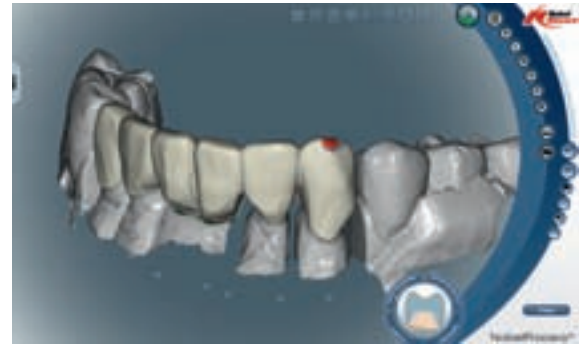

Fig 3 Screenshot of the bridge construction whilst it is being designed on the computer (NobelProcera System, Nobel Biocare). Contact areas are indicated in colour to ensure optimal occlusal relations.

appropriate milling strategies and coordinated milling systems are employed, advanced PMMA composites such as Telio CAD can be used to produce temporary restorations by a fully automated process, resulting in a level of marginal precision that can be achieved manually only at very high expense. In addition, the properties of machinable composites provide clear mechanical advantages over conventional temporary materials.

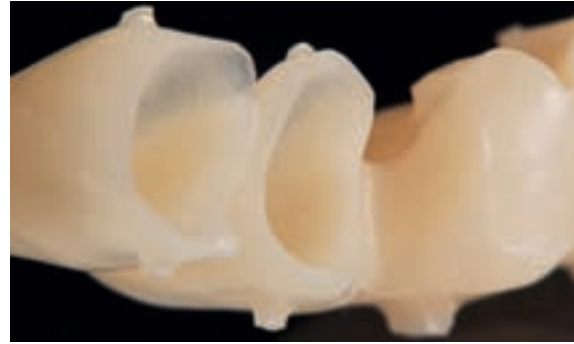
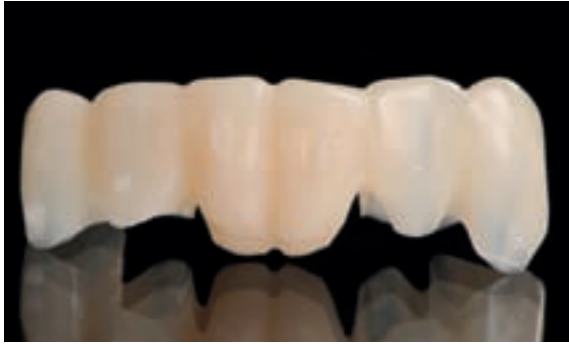
CAD/CAM technology offers significant advantages. For instance, CAD software enables dental technicians to optimally design the morphology of crowns and bridges and adjust the contact areas to the opposing dentition with the help of a virtual "tooth library" (eg based on the SR Phonares® tooth moulds). In addition, industrially milled restorations eliminate the need for an additional finishing step before they can be inserted. High-gloss polishing is all it takes. If maximum esthetics is required, the milled frameworks may be manually reduced in the cut-back technique and the incisal areas may be customized with a light-curing composite material (Telio Lab LC Veneer) or with a two-component PMMA-based powder/liquid system (Telio Lab). Working steps that used to take several hours in the past can be completed in a few minutes in future. Highly esthetic anterior restorations present an additional area of application. Here, indecisive patients may find it helpful to compare two different tooth moulds/morphologies before the final ceramic restoration is created.

Case presentation

Teeth 31 and 41 of this female 52-year-old patient could not be incorporated into a final restoration and had to be extracted because of extensive periodontal defects. As the patient categorically rejected implant treatment, the only option was to restore the lower anterior region with a conventional bridge. It was planned to insert a CAD/CAM temporary to wait until the extraction sockets have healed and the resulting changes in the alveolar ridge have become manifest before placing the final restoration.

Manufacturing the temporaries

In a first treatment step, the bridge abutments were prepared and provided with chairside temporization and a conventional impression was taken (Figs 1a and b). In the dental laboratory, teeth 31 and 41, which had been left in situ, were separated from the master model and subsequently the model was digitized with a dental scanner (NobelProcera Scanner, Nobel Biocare, Switzerland) and a fully anatomical bridge framework (from 33 to 43) was designed in a virtual format using appropriate software (NobelProcera Software, Nobel Biocare) (Figs 2 and 3). Selecting a temporary material suitable for the given indication plays a decisive role in ensuring an efficient workflow in the dental laboratory. A user-friendly software interface for the digital design of the construction also decisively contributes to the overall result. In addition to



Figs 4a and b “Ready-to-use” CAD/CAM manufactured TelioCAD by NobelProcera temporary. The remaining nibs are quickly removed and the temporary is polished to a high gloss before it is inserted (a). Because of the specific properties of Telio CAD, the crown margins can be designed in a thin thickness, reducing the risk of chipping (b: close-up).

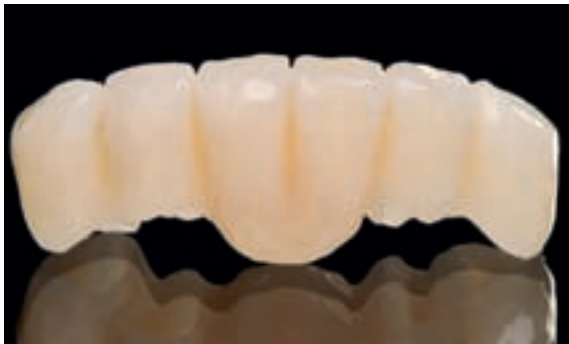

Fig 5 This is the temporary shown in Figure 4 after it has been customized by means of the cut-back technique and Telio Lab. Basal overcontouring enables quick adaptation of the base surface to the clinical situation.

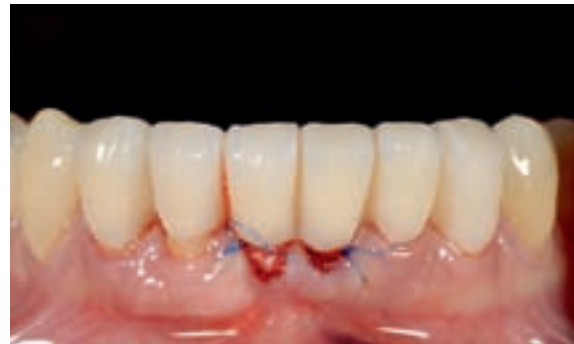

Fig 6 Intraoral view of the temporary in situ after extraction and socket preservation of the extraction sites

fully anatomical design options and straightforward customization processes, the software should also automatically adjust the shape and dimension of the connectors between the bridge pontics and anchors to impart adequate strength to the reconstruction to withstand the continuous loads in the oral cavity.

After the industrially produced Telio CAD by NobelProcera temporary had been milled (Figs 4a and b), it was customized with Telio Lab in a second step (Fig 5) to meet the esthetic expectations of the patient.

Upon completion of the temporary, the two anterior teeth were extracted in a second treatment session. After the teeth had been removed, the tooth sockets were filled with graft material (Bio-Oss® Collagen) and covered with a collagen membrane (Bio-Gide® Perio, both from Geistlich Biomaterials, Germany) to reduce resorption-induced changes in the sockets. Immediately afterwards, the base surfaces of the individualized CAD/CAM temporary was adapted to the clinical situation and the temporary was inserted using the dual-curing temporary composite cement Telio CS Link (Fig 6).

Conclusion

CAD/CAM technology helps save valuable working time both in the dental laboratory and practice. These time savings enable dental professionals to focus on the central aspects of the treatment, such as optimum treatment

planning or customized veneering of frameworks. The introduction of new materials for CAD/CAM restorations has substantially extended the range of indications. It is now possible to offer high-quality components in both standard and customized versions to meet the expectations of patients, providing an advantage to both the dental team and patient. □

Contact details:

PD Dr Stefan Holst
Universitätsklinikum Erlangen
Zahnklinik 2 – Zahnärztliche Prothetik
Glückstr. 11
91054 Erlangen
Germany
stefan.holst@uk-erlangen.de



Prof Dr Manfred Wichmann
Universitätsklinikum Erlangen
Zahnklinik 2 – Zahnärztliche Prothetik
Glückstr. 11
91054 Erlangen
Germany

Nicola Pfennig, MDT
DentalX GmbH & Co KG
Lachnerstr. 2
80639 Munich
Germany



Combination of digital and analogue techniques

Anterior tooth restorations with IPS Empress® CAD Multi

Dr Gunpei Koike, Kanagawa/Japan

Nobody will deny that esthetics play a crucial role in the restoration of anterior teeth, irrespective of whether the restorations are placed in male or female patients. As the final outcome is also dependent on the skills of the clinician, the esthetic differences may be tremendous even if state-of-the-art techniques and materials are utilized. For the anterior restorations in the case presented, I used IPS Empress CAD leucite glass-ceramic blocks. These blocks are offered in two different levels of translucency by the manufacturer. Additionally, a Multi Block featuring multiple shades is available. As these blocks are industrially processed, restorations of consistent quality are achieved. The glass-ceramic material is easy to polish or reduce, which enables the milled restoration to be veneered subsequently. As a result, the final esthetic outcome can be optimized in a simple fashion.

I usually work with the polychromatic IPS Empress CAD Multi blocks, as they feature a true-to-nature gradation of shades combined with optimum levels of brightness and translucency. Consequently, they seamlessly blend in with the natural oral environment. In addition, they demonstrate lifelike fluorescence.

Today, the patients' needs and expectations differ very widely. They may include quick healing, but also long-term stability or enhanced esthetics. The use of IPS Empress CAD Multi blocks in combination with the CEREC® 3 (Sirona) chairside CAD/CAM system allows restorations to be fabricated that meet the needs of today's patients. In the case presented, a restoration was fabricated with an IPS Empress CAD Multi block. A highly esthetic result was achieved that left nothing to be desired.

Case study

A 32-year-old female patient who presented to my office was dissatisfied with the esthetic appearance of her upper anterior teeth. The incisal edges showed an irregular con-

tour and discolouration was present (Fig 1). The initial examination revealed an inconsistent incisal line as well as dark discolouration visible during smiling. Tooth 12 had previously been restored with a crown, while tooth 22 had received a composite restoration (Fig 2). Prior to the start of the treatment, a CRT test was conducted. The results of the test showed a low caries risk level and good oral hygiene. Therefore, the restorative treatment could be started immediately after conducting the test.

The restorative options available to the patient were discussed with her. Her priorities included the lightening of the discoloured teeth, as well as the creation of softer, more feminine tooth shapes and the creation of long-lasting restorations.

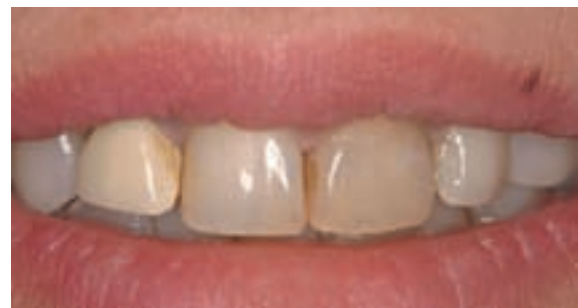

Fig 1 Preoperative situation showing an irregular incisal line. The patient considered her teeth to be too "angular and big".

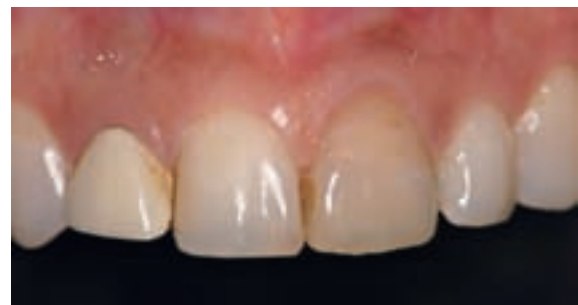

Fig 2 Tooth 12 had been restored with a crown in the past and tooth 21 showed pronounced discolouration.

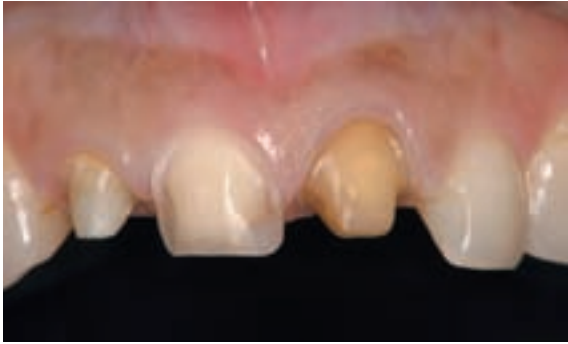

Fig 3 Preparation for a CAD/CAM-fabricated all-ceramic restoration with rounded angles and transitions

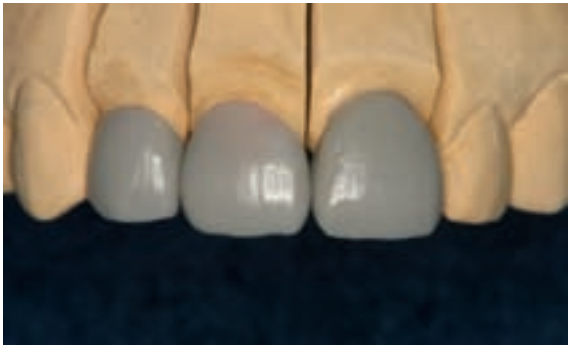

Fig 5 Creation of the wax-up. As desired by the patient, more "rounded" tooth shapes were established.

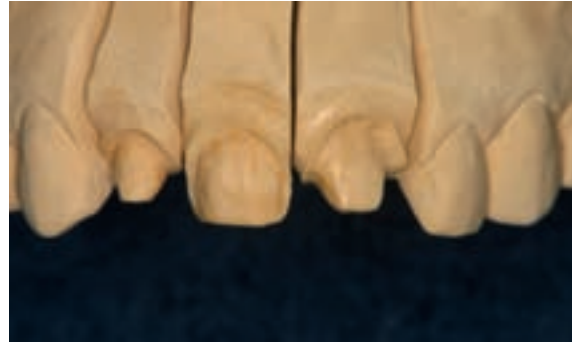

Fig 4 The die model constituted the basis for the mock-up.

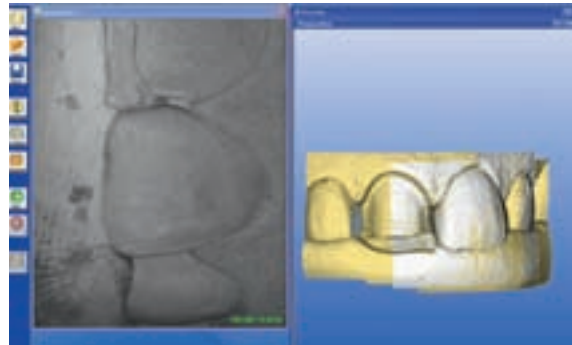


Fig 6 The restoration was designed on the computer screen. The silicone matrix was scanned in order to be able to construct the incisal area easily and quickly.

Based on her wishes, an anamnesis and a diagnostic analysis were conducted. In a next step, I set up a treatment plan which included teeth 11, 12, 21 and 22.

First I fabricated a mock-up which was to serve as a basis for the discussion with the patient. Her wish of having teeth with a more rounded shape and thus with a softer, more feminine touch was already taken into account during the fabrication of the mock-up. The teeth were prepared according to standard procedures (Fig 3). A fibre-reinforced endodontic post and core was seated in tooth 12. This was done to prevent root fracture but still ensure an esthetic restorative result. In tooth 11, caries was detected in the area of the medial angle. Following removal of the carious tissue, the cavity was filled with composite resin. Tooth 21 received a full crown preparation. A rounded shape was prepared to ensure even distribution of the force to which the restoration would be exposed. In tooth 22, composite material was applied in the area of the medial angle.

The CEREC software features a tool called "correlation mode". This mode enables users to take an optical impression. As the patient had a very clear idea of the future appearance of her teeth, I decided to use this mode to match my ideas with hers. Therefore, a silicone impression was taken after the teeth had been prepared and a model was poured (Fig 4).

Based on the mock-up, which had been discussed with the patient earlier, a wax-up was created on the model and an optical impression was taken (Fig 5). The recorded model served as a guide for the construction procedure, which was carried out using the quadrant mode.

In the fabrication of anterior restorations it is advisable to continuously check the size and dimension of the incisal build-up from the palatal aspect by means of a silicone matrix. This significantly facilitates the modelling procedure. Moreover, by proceeding in this way it becomes apparent immediately if data has been lost during optical impression taking. A loss of information in the area of the incisal edge usually renders the construction of anterior restorations considerably more difficult. The precise recording of data is of utmost importance, especially if the patient requests a particular tooth shape (Fig 6).

The 3.6 version of the CEREC 3D software has a milling preview feature, which allows users to "place" the restoration in the virtual block as needed in accordance with the gradation of shades from cervical to incisal (Fig 7). This enables the operator to make use of the opaque/translucent areas or the gradation pattern of the block in an optimal fashion. If several teeth are restored simultaneously, there are now various options to utilize the different areas efficiently. Consequently, it is even possible to fabricate restorations that do not require individual characterization or cutting back.

The versatility and flexibility of the IPS Empress CAD Multi block is thus further enhanced. After the restoration had been milled, it was seated on the model. The restoration showed an excellent fit. Due to the gradation of opaque and translucent shades from the cervical to the incisal region, the restoration had a very natural appearance (Fig 8).

In the case presented, the restorations were glazed but did not have to be characterized because of the IPS Empress CAD Multi block's lifelike esthetics. The reason why I




Fig 7 Virtual positioning of the restoration in the IPS Empress CAD Multi block

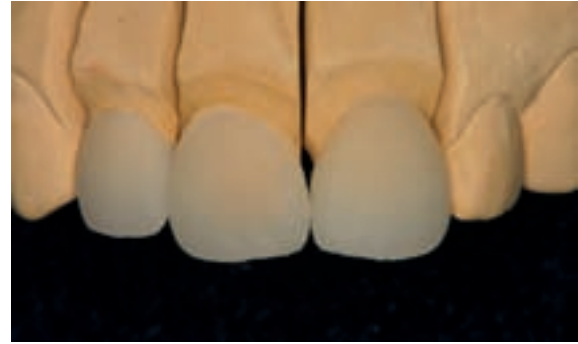

Fig 8 The milled restorations seated on the model show an excellent fit.

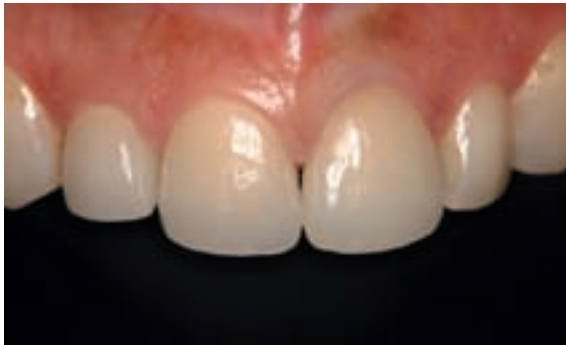

Fig 9 The adhesively cemented IPS Empress CAD Multi restorations show the typical gradation of shade from the cervical to the incisal area and thus harmoniously blend into the oral environment.

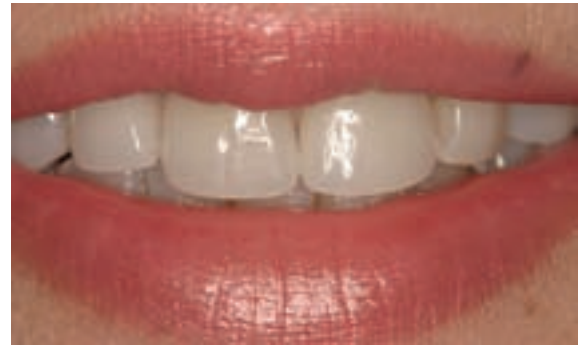

Fig 10 The lip line of the happy patient three years after completion of the treatment. The restorations are in an impeccable state and still have an outstandingly esthetic appearance.

glazed the restoration was not primarily to improve its esthetic appearance, but to impart it with even higher strength. In the literature, glaze firing is generally referred to as a means of increasing the strength of IPS Empress CAD restorations. I would like to point out, however, that IPS Empress CAD restorations also possess sufficient strength to ensure successful, long-term results if they are merely polished. Following try-in, the restorations were adhesively cemented (Fig 9).

Particularly in the cementation of veneers, strict adherence to the cementation protocol is crucial to ensuring long-lasting results. Normally I use Variolink® II luting composite, since it allows (thin) all-ceramic restorations to be reliably, durably and esthetically cemented. In the case presented, I decided to use the universal luting composite Multilink® Automix as it is very easy and convenient to use. The restorations are reliably cemented in just two steps. The high bond strength and long-lasting adhesion that are achievable with this system have been confirmed by numerous studies conducted in recent years. In contrast to Variolink II, Multilink Automix is only available in three different shades (yellow, transparent and opaque). As the patient's teeth did not show any severe discolouration, the choice of materials was sufficient in this case.

Figure 10 shows the restorations three years after completion of the treatment. The restorations still look attractive and the gingival tissue has a healthy colour. We are proceeding on the assumption that the dark triangle between the two front teeth will become smaller over time. The four teeth could be restored with IPS Empress CAD Multi in a very satisfactory fashion and the patient was very pleased with the result.

Summary

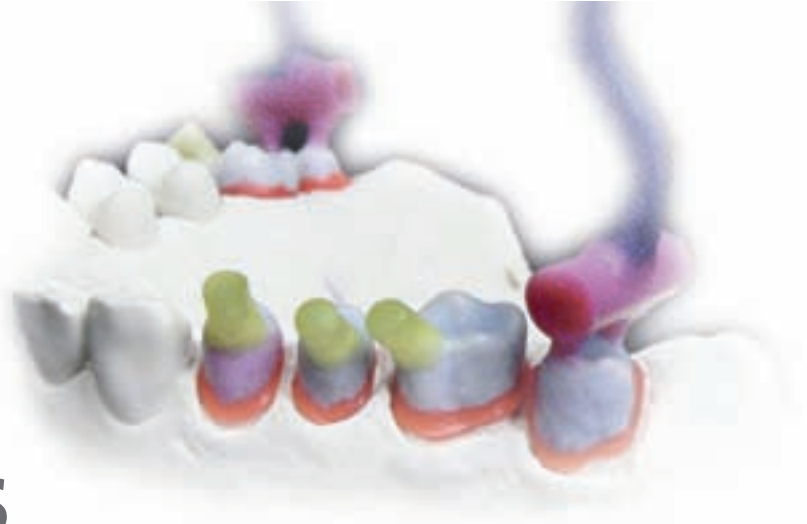
In Japan, it is generally assumed that conventional, laboratory-based restorative procedures are superior to computer-assisted techniques. Some experts are of the opinion that CAD/CAM-based systems even pose a threat to the profession of laboratory technician as a whole. In my opinion this is a huge misconception. On the contrary, CAD/CAM technology and the manual skills of laboratory technicians can be ideally combined to achieve optimal results. The flexible use of digital and analogue techniques helps to better fulfil patient needs and takes modern dentistry to the next level.

This position is corroborated by the case presented in this article, which was restored by making full use of the possibilities offered by the CEREC system and the IPS Empress CAD Multi block. I will continue to provide my patients with high-quality restorations, also by using sophisticated procedures. These procedures ensure that durable results and thus a high level of patient satisfaction are achieved. □

Contact details:

Koike Dental Clinic
Dr Gunpei Koike
1-20-1 Nobi Yokosuka
Kanagawa 239-8041
Japan
www.koikedc.com
www.cerec.jp





All-ceramics encounter PFM ceramics

IPS e.max® combined with IPS InLine®

Hana Jelínková, Písek/Czech Republic

Obtaining harmonious esthetic results with two different veneering materials is a considerable challenge that is not without its risks. Situations in which dental technicians are forced to use several different veneering materials to satisfy the needs of their customers are determined by biological factors and the financial means of the patients. All the ceramic veneering materials on the market differ in their chemical compositions, which are responsible for the final appearance of the restoration. In addition, the influence of the framework material should not be underestimated. If it hinders the transmission of light, the esthetics of the restoration will be compromised. So, how do we obtain truly “perfect” results?

We tend to choose products that can be combined on the basis of their optical compatibility. For this purpose, we often have to rely on the many years of experience we have gathered working with the materials from different manufacturers. However, we have also found that we can take an easier route by using the products from manufacturers who supply materials that are coordinated in terms of their shade. Manufacturers who focus their efforts on solving the problem of optical compatibility among their different materials strive to offer their products in integrated systems.

Case study

On the basis of the following case, we would like to show how two different materials can be successfully combined. The patient's teeth 14, 15, 16 and 17 as well as 26 and 27 were restored with provisional crowns. For the permanent restoration of these teeth, a combination of all-ceramics (IPS e.max) and PFM ceramics (IPS InLine) was chosen: Metal frameworks veneered with the leucite-based feldspathic ceramic IPS InLine were combined with lithium disilicate glass-ceramic frameworks veneered with the nano-fluorapatite glass-ceramic IPS e.max Ceram. The patient chose this solution because of financial reasons.

In the fabrication of the restorations, the specifications of the shade diagram as well as the recommended layer thicknesses of the individual materials were observed. The latter aspect was of particular importance due to the different shrinkage characteristics of the two ceramics.

The individual IPS InLine and IPS e.max Ceram veneering materials (eg Dentin, Incisal and Effect materials) not only have consistent designations, their shades are also coordinated. Before the metal frameworks in the present case were veneered with IPS InLine, the substrate had to be completely covered with an opaquer layer to mask the metal. The IPS e.max lithium disilicate frameworks did not require this coating, as the materials for the fabrication of the substructures are available in many different shades and levels of translucency. Nonetheless, we were able to follow the same shade diagram once we had placed the layer that would mediate the required adhesive bond (after foundation and opaquer firing respectively). This enabled us to obtain the desired harmonious appearance of the restorations. IPS InLine and IPS e.max Ceram differ slightly with regard to their translucency. However, this aspect is quite useful in the subsequent layering procedure. We attenuated and masked the opaqueness of the metal frameworks, while we enhanced the translucent properties of the lithium disilicate by applying the IPS e.max

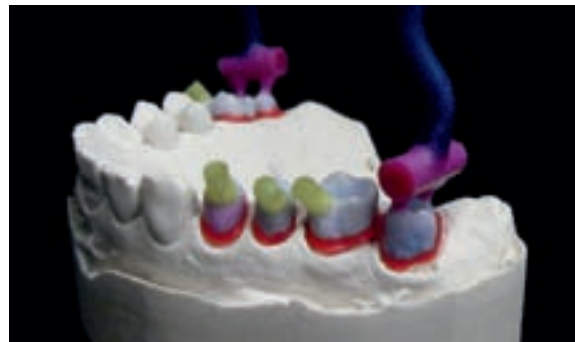

Fig 1 Waxed-up teeth with sprues

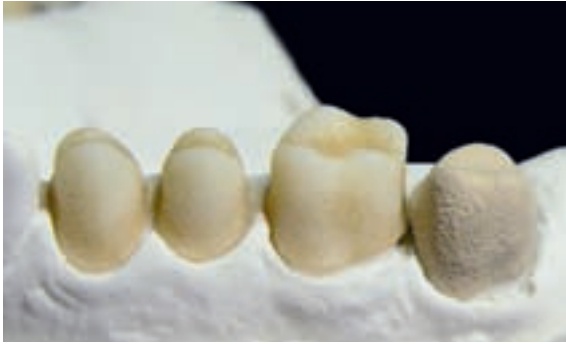

Fig 2 An adequately thick coating of opaquer is applied.

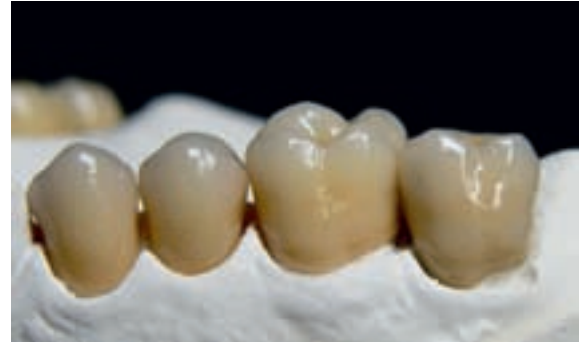
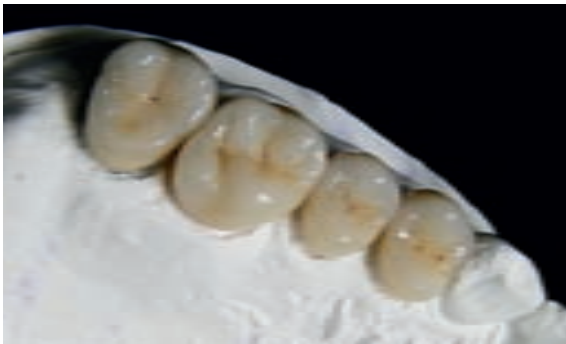
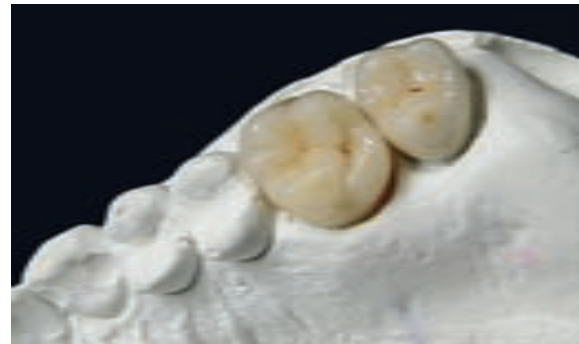Fig 3 All-ceramic restorations



Figs 4 and 5 The finished crowns on the model



Ceram all-ceramic. The veneering steps for the two different types of restorations are very similar. In the case at hand, the teeth were waxed up according to the instructions of the manufacturer: the IPS e.max Press lithium disilicate frameworks with a minimum final thickness of 0.8 mm and the metal frameworks (CrCo alloy) with a thickness of minimum 0.4 mm. Both types of restorations were built up anatomically, that is, with supported cusps and crown margins, in order to obtain an even thickness of the veneers. This detailed wax-up provides the basis for creating restorations with maximum esthetics and function. Next, the sprues were attached to the wax-ups (Fig 1). After the press and casting procedures, the substructures were coated with a wash and opaquer layer respectively in preparation for the subsequent layering procedure.

The metal frameworks were completely masked with opaquer (Fig 2) and shoulder powders were evenly sprinkled onto this layer. Excess was carefully removed. This step improves adhesion and optimizes light refraction through the crystals of the Margin material. This effect attenuates the opaqueness of the PFM restoration. It is clearly visible in the finished restoration.

We followed a similar procedure for the all-ceramic substructures. If the framework had to be (partially) shaded, we used IPS e.max Ceram Shades instead of the opaquer. The remaining surfaces were coated with a thin layer of glazing liquid. Then we used the sprinkle technique to distribute IPS e.max Ceram Dentin on the frameworks. In the fabrication of restorations with lithium disilicate substructures, the achievement of light scattering is secondary. Rather, the focus in this type of restoration is on adhesion. After firing, the surfaces are

slightly rough, which mediates the desired bond between the framework and the layering material.

In the present case, the metal-reinforced crowns were built up first. Due to the versatility of all-ceramics, the desired harmony with regard to shades and opaqueness is easier to achieve with these materials than with PFM materials. In order to obtain an overall esthetic result, therefore, the all-ceramic restorations were fabricated last (Fig 3). Figures 4 and 5 show the finished crowns on the model with the gingival contour. The adhesive luting composite Multilink® Automix was used to cement all the crowns. This luting composite is suitable for the cementation of PFM and all-ceramic restorations.

Conclusion

The present case shows that the combination of PFM ceramics and all-ceramics can produce excellent esthetic results. Coordinated materials and shade systems make it easy to use different types of ceramics in one restoration and allow materials such as the Effect materials to be used to their fullest effect. With the help of conventional shade diagrams, the desired results can be achieved quickly and easily. □

Contact details:

Hana Jelínková
K-dent.pi s.r.o.
Heydukova 101
397 01, Písek
Czech Republic





Distinguished by innovation

Healthy teeth produce a radiant smile. We strive to achieve this goal on a daily basis. It inspires us to search for innovative, economic and esthetic solutions for direct filling procedures and the fabrication of indirect, fixed or removable restorations, so that you have quality products at your disposal to help people regain a beautiful smile.

www.ivoclarvivadent.com

Ivoclar Vivadent AG

Bendererstr. 2 | FL-9494 Schaan | Liechtenstein | Tel.: +423 / 235 35 35 | Fax: +423 / 235 33 60

635402

ivoclar .
vivadent®
passion vision innovation